ORIGINAL ARTICLE

CT Evaluation of Cholangiocarcinoma and its Correlation with Endoscopic Retrograde Cholangiopancreaticography

Shalini Goel*, Apar Mathur, Juhi Agrawal**, Pankaj Kumar Nitharwal***, RajatSinghal**, Mukesh Mittal******

ABSTRACT

Introduction: Cholangiocarcinoma (CC) is the most frequent malignant tumour of the biliary tract, accounting for 10-20% of all primary liver tumours. It may occur at any segment of the bile duct, i.e. from the terminal ductules to the ampulla of Vater. Therefore, CC tumours are differentiated in intrahepatic (iCC) and extrahepatic (eCC) tumour and the iCC is subdivided into peripheral and perihilar CC (pCC), the latter also being called Klatskintumour. Various imaging modalities are available to accurately diagnose cholangiocarcinoma such as imaging modalities including contrast enhanced Computed tomography (CT) of abdomen in triple phase and MRCP which is a non-contrast MR technique in which the T2-weighted contrast between bile (long T2) and adjacent tissues (short T2) is accentuated by using heavily T2-weighted sequences, and other invasive modalities in endoscopic retrograde cholangiopancreaticography (ERCP), which is retrograde injection of contrast agent into the biliary tract allows the assessment of localization and morphology of bile duct strictures. Out of these currently ERCP is considered gold standard for hilar patency.

Aims and objective: To determine accuracy of hilar patency as assessed by CECT with gold standard of ERCP.

Materials and methods: In this prospective study, 50 consecutively registered patients (24 women, 26 men; mean age, 55 years; range, 34-81 years) with clinical / sonographic suspicion of cholangiocarcinoma were examined between May 2017 to May 2019 in tertiary care hospital. All patients were scheduled to undergo triple phase computed tomography (TPCT) based on the patient's reports and symptoms. Following TPCT, ERCP was done in indicated patients.

Inclusion and exclusion criteria: Adult patients of either sex who were clinically / sonographically suspected cases of cholangiocarcinoma referred by gastroenterology/ gastro surgery department were included in the study.

Patients with history of allergy to iodinated contrast agent, and those with renal insufficiency (serum creatinine concentration > 1.5 mg/dL) were excluded.

Sample size: A sample size of 50 adult patients of either sex was taken referred to us by gastroenterologist/ gastro surgeons suspected of having cholangiocarcinoma.

Conclusion: The diagnostic accuracy of CECT is comparable to the gold standard ERCP in the evaluation of hilar patency.

INTRODUCTION

Cholangiocarcinoma (CC) is the most common malignancy of the biliary tract and it account for 10-20% of all primary liver tumors. Most (95%) of CC are adenocarcinomas with a high proportion of fibrous stroma. Despite recent advances in patient care, surgical resection of the tumor remains the only potentially curable therapy, leading to a 5-year survival of 30-35%. CC may occur at intrahepatic (iCC) or extrahepatic (eCC) (27-42%) locations; the iCC is subdivided into peripheral (6-8%) and perihilar CC (pCC) (50-67%), the later also being called Klatskin tumor. The etiology of CC is not fully understood, but several risk factors like primary sclerosing cholangitis (PSC), liver fluke infestations (Opisthorchis viverrini, Clonorchissinensis),

*Junior Resident, Department of Radiodiagnosis, G.I.P.M.E.R, New Delhi
**Senior Resident, ***Assistant Professor, ****Professor, Department of Radiodiagnosis, SMS Medical College, Jaipur.
Corresponding Author:
Dr. Apar Mathur
Senior Resident, Radiodiagnosis, SMS Medical College, Jaipur.
Address -B-258, Janta Colony, Jaipur, Rajasthan. PIN CODE- 302004
Mail ID- draparmathur@gmail.com
Mobile Number : 9983892999

hepatolithiasis, Thorotrast exposure, and choledochal cysts have been identified. The Liver Cancer Study Group of Japan classified iCC into three types based on the dominating morphologic feature: mass-forming (the most common), periductal infiltrating, and intraductal growth. Growth pattern of eCC is classified as sclerosing, nodular and papillary. Imaging modalities like ultrasound, computed tomography, magnetic resonance imaging, and also positron emission tomography/computer tomography are useful in the diagnosis, primary staging, and restaging of CC[1]. Computed tomography (CT) is a commonly used approach for the detection and staging of cholangiocarcinoma. In the arterial phase of CT scan, arterial anatomy of the liver and surrounding structures can be visualized which aids in planning of surgery. In the portal venous phase, CC mainly show incomplete rim-like contrast enhancement at the tumor periphery and low intratumoural attenuation, increasing the precision in estimating the tumor size and the detection of satellite nodules. In late-phase scans (5-10 min after contrast injection), a late enhancement of the tumor can be observed, representing the amount of fibrous stroma. In case of tumor necrosis and/or mucin-containing cells, the delayed enhancement may disappear. CT scan helps indiagnosis of dilated bile duct, assessment of liver parenchyma, vascular encasement, lymph node, and metastasis. Additionally, CT is useful for detecting the presence of liver atrophy. Dilatation of bile ducts combined with atrophy suggests the obstruction of the portal vein[2]. In endoscopic retrograde cholangiopancreaticography (ERCP), retrograde injection of contrast agent into the biliary tract allows the assessment of localization and morphology of bile duct strictures. On the findings of asymmetric, irregular strictures malignancy is suggested. Moreover, resectability can be evaluated. Compared to non-invasive imaging techniques, ERCP allows tissue collection for cytological and histological investigation, allows biliary stent implantation as palliative treatment in irresectable tumors or as a preoperative procedure prior to definitive/ curative surgery. ERCP would also be helpful in definitive diagnosis of primary sclerosing cholangitis which is a major risk factor for development of CCA. ERCP has evolved from a diagnostic procedure into a primarily therapeutic procedure for a variety of biliary and pancreatic disorders[3].ERCP is associated with a risk of infection known as, ascending cholangitis thought to be related to instrumentation of poorly draining, obstructed bile ducts.

In addition to FDA-mandated post-marketing surveillance of duodenoscope high-level disinfection guidelines from each manufacturer, proposed solutions to address duodenoscope contamination have included a culture and quarantine process following disinfection and before reuse, ethylene oxide gas sterilization, and a call for disruptive technology, including disposable single-use duodenoscopes and redesigned forceps elevator mechanisms. Human factors must also be considered as a potential contributor. Instruments that have not undergone adequate manual disinfection can still harbour living bacteria, even after gas sterilization with ethylene oxide[4].

Despite the threats and challenges as detailed, abundant opportunities exist for novel ERCP applications. Duodenoscope-assisted cholangiopancreatoscopy has evolved to single-operator platform with high-resolution imaging capabilities that can support a range of intraductal applications, from direct visualization and targeted sampling of intraductal neoplasm, to lithotripsy of bile duct and pancreatic duct stones. Therapeutic intervention for chronic pancreatitis, including stent placement and/or treatment of pancreaticolithiasis, the later often supported by either pancreatoscopy-targeted intraductal lithotripsy or extracorporeal shockwave lithotripsy, represent a potential area of expanded opportunity for ERCP[5]. The use of Self Expandable Metallic Stent (SEMS) for treatment of benign bile duct strictures, including those related to cholecystectomy, liver transplant, and chronic pancreatitis, is associated with high technical and clinical success rates and requires fewer ERCPs per patient to achieve stricture resolution compared with use of plastic stents[6]. Addition of photodynamic therapy to biliary stent therapy may prolong overall survival compared with biliary stent therapy alone and may prolong metal stent patency in patients with unresectable cholangiocarcinoma[7].

AIMS AND OBJECTIVE

To determine accuracy of hilar patency in cholangiocarcinomaas assessed by CECT with gold standard of ERCP.

MATERIALS AND METHODS

The study protocol was approved by the institutional research review board, and informed consent was obtained from all patients. In this prospective study, 50 consecutively registered patients (24 women, 26 men; mean age, 55 years; range, 34-81 years) with clinical / sonographic suspicion of cholangiocarcinoma were examined between May 2017 to May 2019. All patients were scheduled to undergo triple phase computed tomography based on the patient's reports and symptoms. Following TPCT, ERCP was done in indicated patients.

STUDY DESIGN

It is a type of descriptive cross- sectional study.

STUDY LOCATION

This study was conducted in the department of Radio-diagnosis, G.I.P.M.E.R, New Delhi in association with the department of Gastroenterology, G.I.P.M.E.R., New Delhi

STUDY DURATION

The study was conducted for two years from June 2017 to May 2019.

INCLUSION AND EXCLUSION CRITERIA

Adult patients of either sex who were clinically / sonographically suspected cases of cholangiocarcinoma referred by gastroenterology/ gastro surgery department were included.

Patients with history of allergy to iodinated contrast agent, and those with renal insufficiency (serum creatinine concentration > 1.5 mg/dL) were excluded.

SAMPLE SIZE

A sample size of 50 adult patients of either sex was taken referred to us by gastroenterologist/ gastro surgeons suspected of having cholangiocarcinoma.

METHODOLOGY

COMPUTED TOMOGRAPHY IMAGING TECHNIQUE-

The complete CT study was explained to each subject with risk involved during and / or after intravenous contrast administration and radiation exposure during the CT study and written and informed consent was taken. Renal function tests were checked before intravenous contrast administration.

Image acquisition was carried out abide by ALARA (As Low as Reasonably Achievable) principle, which required careful patient preparation and scanning technique. Scans were performed in a cephalic to caudal direction, during shallow inspiration breath hold with scan range from lung bases to the pubic symphysis.

CT parameters used tube voltage 100 kVp, tube current 150 mAs, 1ml/kg of non-ionic contrast agent (350mg of iodine/ml) was injected at the rate of 5ml/s through an 18G intravenous antecubital cannula.

For cholangiocarcinoma, triple phase contrast study was done with following phases:

1. Pre-contrast CT
2. Late arterial phase CT performed 20–30 seconds after contrast medium injection.
3. Hepatic venous phase CT is performed 25–30 seconds after the completion of late arterial phase scanning.
4. Delayed phase scanning (performed 150–180 seconds after the completion of hepatic venous phase scanning)

Evaluation

Acquired data was evaluated in axial, coronal, and sagittal sections and with various post processing methods to look for, site / size / type / margins of lesion, CBD, CHD and IHBR dilatation, enhancement pattern, vascular infiltration, lymph nodes involvement, metastatic lesions and hilar patency.

Radiological diagnosis was made based on above mentioned findings. Histopathological correlation was done to evaluate the efficacy of CT in diagnosis of cholangiocarcinoma. ERCP was performed after CT evaluation to look for hilum patency in indicated patients. Final diagnosis was made with histo-pathological evaluation and ERCP for hilar patency

STATISTICAL METHODS

The collected data was entered in excel sheet and analysed using SPSS-20 version. Statistical analysis of acquired data is done by calculating the sensitivity, specificity, positive predictive value, negative predictive value, and accuracy of TPCT in diagnosing and staging cholangiocarcinoma. TPCT was correlated with ERCP for hilar patency. Quantitative data was expressed as mean, standard deviation and difference between groups was tested by student's t-test. Nonparametric test like Mann Whitney 'U' test were used if required. While qualitative data was expressed in percentage. Difference between proportions was tested by chi-square test or fisher's exact test. 'P' value less than 0.05 was considered statistically significant.

OBSERVATION

50 patients were included in the study. Out of 50, 45 (90%) patients had one lesion. only 3 (6%) patients had 2 lesions and 2 (4%) patients had multiple lesions. (Table-1). Out of 50, 45 patients (90%) had lesion having irregular margins. only 1 patient (2 %) had lesion having polypoidal margins and 4 (8%) patients had smooth surface lesion. (Table-2). Out of 50 patients, 32 patients (64%) had lesion showing irregular peripheral enhancement with gradual centripetal enhancement. Lesion showing heterogeneous enhancement was noted in 14 patients (28%), homogenous enhancement of wall thickening is noted in 3 patients (6 %) and homogenous enhancement of lesion is noted in 1 patient (2 %) (Table-3). Out of 50 patients, CBD is dilated in 20 patients (40 %). CBD is not dilated in 30 (60 %) patients (Table-4)

Out of 50 patients on TPCT, hilum was patent in 25 patients (50%) and was not infiltrated by the lesion. Hilum was infiltrated by the lesion in another 25 patients (50%). ERCP was done in 43 patients and hilum was patent in 21 patients and was not patent in 22 patients (Table-5)

Table 1: Hilar patency on CT/ERCP

No. of lesions	No.	%
1	45	90
2	3	6
Multiple	2	4

Table 2: Margins of lesion in study subjects

Margins of lesion	No.	%
Irregular	45	90.0
Polypoidal	1	2.0
Smooth	4	8.0

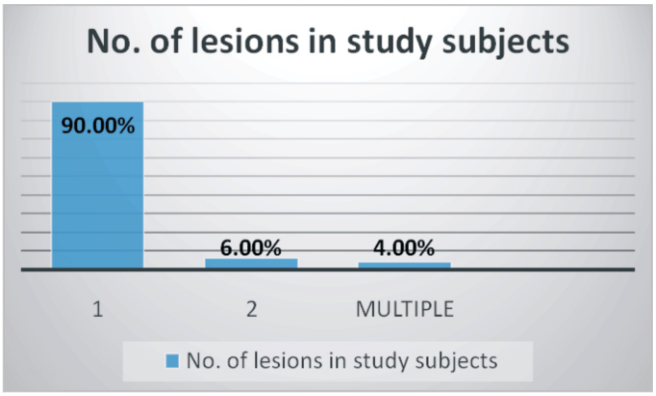

Bar chart showing distribution of number of lesions in patients

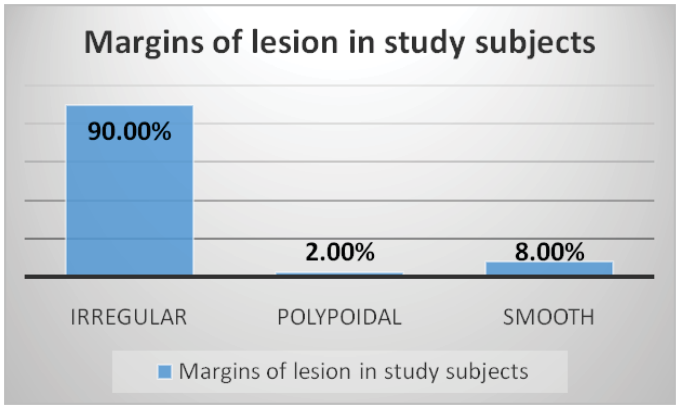

Bar chart showing distribution of lesion margins in patients

Table 3: Enhancement pattern of lesion in study subjects

Enhancement pattern of lesion	No.	%
Heterogeneous enhancement	14	28.0
Irregular peripheral enhancement with gradual centripetal enhancement	32	64.0
Homogenously enhancement	1	2.0
Homogenously arterial enhancement of wall thickening	3	6.0

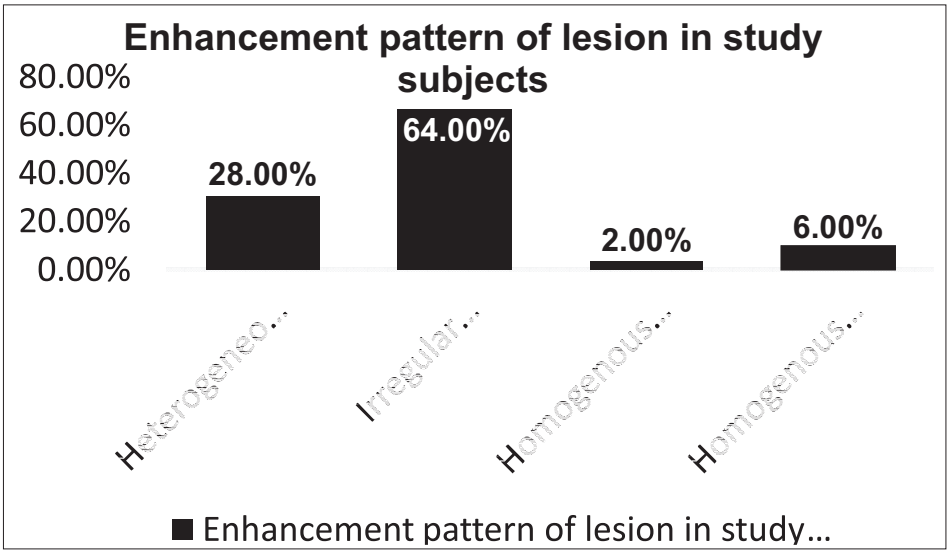

Bar chart showing enhancement pattern of lesion in patients

Table 4: CBD status

CBD status	No.	%
Dilated	20	40.0
Non-dilated	30	60.0

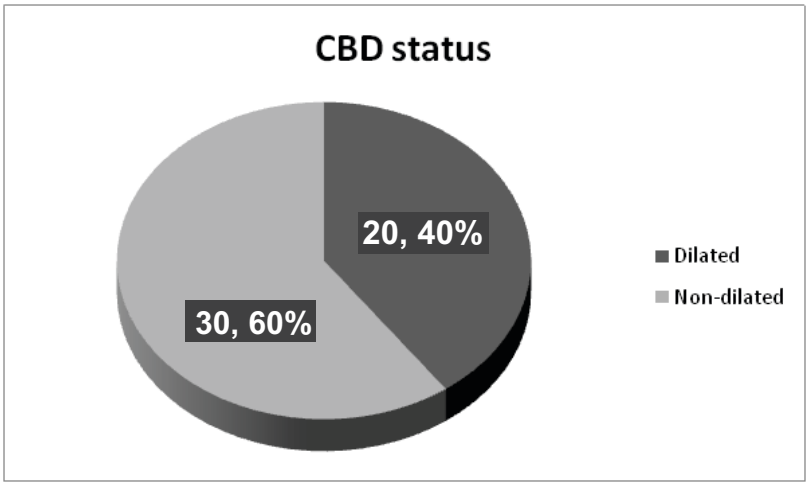

Table 5: Hilar patency on CT/ERCP

Hilar Patency	CT (n=50)	ERCP (n=43)
A	25	22
P	25	21

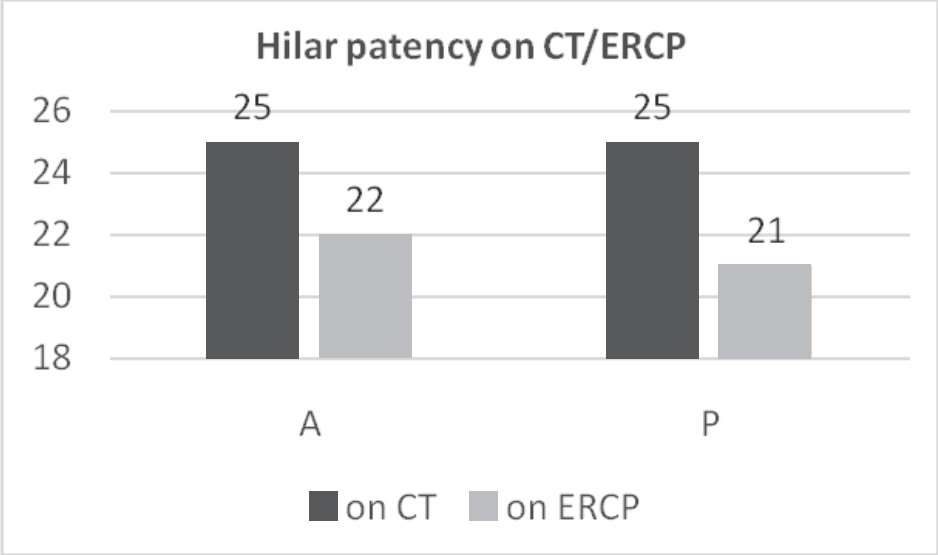

Bar graph showing comparison of hilar patency on CT and ERCP

Table 6: Diagnostic accuracy of radiological part

Diagnostic value	% (95% CI)
Sensitivity	86.1 (72.1-94.7)
Specificity	71.4 (29.1-96.3)
PPV	94.8 (85.1-98.4)
NPV	45.5 (25.7-66.7)
Accuracy	84.0 (72.9-92.8)

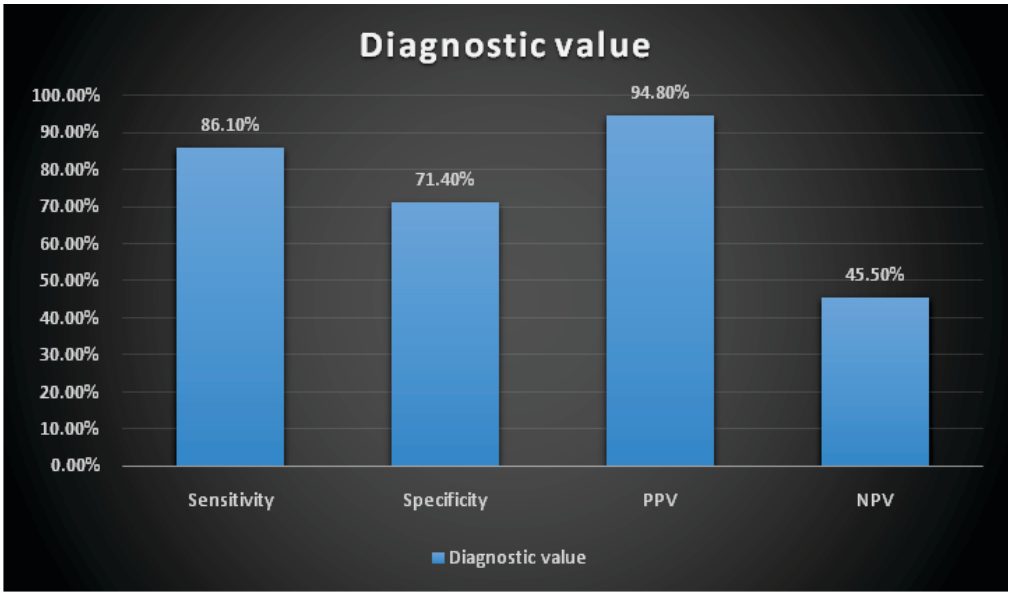

Bar graph showingdiagnostic accuracy of CT in evaluating cholangiocarcinoma in study subjects

RESULT

In this study by CT, hilum was patent and was not infiltrated by the lesion in 25 patients (50%) out of 50 patients while hilum was infiltrated by the lesion in another 25 patients (50%).

ERCP was done in 43 patients and hilum was patent in 21 patients and was not patent in 22 patients.

Based on results, sensitivity of CT in diagnosing CCA is 86.1 %, specificity is 71.4 %, PPV is 94.8 %, NPV is 45.5% and accuracy is 84% (Table-6)

For long, ERCP was the standard established procedure for evaluation of patients with obstructive jaundice. Due to recent advances in MDCT technology permitting faster acquisition in a single breath hold and upgraded software techniques for image reconstruction, MDCT is now more sensitive for determining the preliminary level and cause of obstruction. Due to sub-second acquisition and multiphasic approach, newer studies have further refined the role of MDCT in terms of specific diagnosis and staging of the pathology. So, multiphasic, single breath hold,sub centimetreiso-voxel scanning with post processing through volume acquisition, maximum intensity projections (MIPs), and multiplanar reformations (MPR) all help to increase the diagnostic accuracy, which is immensely helpful in

1. a) Differentiating benign from malignant stricture.
2. b) Staging complicated biliary malignancies in terms of involvement of biliary confluence, invasion, and encasement of the adjacent major arterial and venous channel making it inoperable, as well as regional lymphadenopathy and hepatic metastasis.

Hence, Multiphasic MDCT of the abdomen with pancreatic and venous phase through the hepato-biliary-pancreatic region is now the accepted worldwide protocol for pancreatico-biliary malignancies.

CONCLUSION

The results of this study showed the diagnostic accuracy of CECT is comparable to the gold standard ERCP in the evaluation of hilar patency in cholangiocarcinoma.

REFERENCES

1) Olthof, S. C., Othman, A., Clasen, S., Schraml, C., Nikolaou, K., &Bongers, M. (2016). Imaging of Cholangiocarcinoma. Visceral medicine, 32(6), 402–10.
2) Weber A, Roland M, Christian P. Diagnostic approaches for cholangiocarcinoma. World J Gastroentero. 2008 Jul 14; 14(26): 4131–6.

Parodi A

3) 1, Fisher D, Giovannini M, Baron T, ConioM.Endoscopic management of hilar cholangiocarcinoma. Nat Rev Gastroenterol Hepatol.2012 feb;vol 9:105.
4) Larsen S, Russell RV, Ockert LK, Spanos S, Travis HS, Ehlers LH, Mærkedahl A. Rate and impact of duodenoscope contamination: a systematic review and meta-analysis. EClinicalMedicine. 2020 Aug 1;25:100451.
5) Tandan M, Reddy DN. Extracorporeal shock wave lithotripsy for pancreatic and large common bile duct stones. World journal of gastroenterology: WJG. 2011 Oct 10;17(39):4365.
6) Kwon CI, Ko KH, Hahm KB, Kang DH. Functional self-expandable metal stents in biliary obstruction. Clinical endoscopy. 2013 Sep 30;46(5):515-21.
7) Moole H, Tathireddy H, Dharmapuri S, Moole V, Boddireddy R, Yedama P, Dharmapuri S, Uppu A, Bondalapati N, Duvvuri A. Success of photodynamic therapy in palliating patients with nonresectablecholangiocarcinoma: A systematic review and meta-analysis. World journal of gastroenterology. 2017 Feb 2;23(7):1278.